Original Article

Outcome of Distal Tibial Extra Articular Fracture Fixation by Anatomical Plate Using Minimally Invasive Plate Osteosynthesis Technique

*Biswas T[1], Chanda M[2], Islam DR[3], Newaz KK[4], Islam MR[5], Bhuiyan ARMM[6], Haque MN[7]

Abstract

Background: *Dealing with -articular distal tibial fractures can be tough because the skin and other soft tissues around the fracture are not very strong and the blood supply is not very good. Doctors have started using a technique called minimally invasive plate osteosynthesis (MIPO) with anatomical locking plates to help the bone heal and get better results for patients.* ***Objective:*** *The goal of this study was to see how well extra-articular distal tibial fractures did when treated with plate fixation using the minimally invasive plate osteosynthesis technique.* ***Materials and Methods:*** *The study was conducted with 20 adult patients who had closed -articular distal tibial fractures and treated them with minimally invasive plate osteosynthesis using an anatomically contoured distal tibial locking plate. Olerud–Molander Ankle Score was used to see how well the patients were doing.* ***Results:*** *Fracture healing was achieved in every patient, with radiological union occurring at an average of 18.50 ± 1.93 weeks. Full weight bearing was most commonly attained between 17 and 18 weeks, which was observed in 45% of the patients. In addition, 80% of the patients were able to regain a walking ability comparable to their pre-injury level. Functional recovery, as evaluated using the Olerud–Molander Ankle Score, was satisfactory in 80% of the patients, indicating favourable overall clinical outcomes.* ***Conclusion:*** *Using invasive plate osteosynthesis with an anatomically contoured distal tibial locking plate is a good way to treat extra-articular distal tibial fractures.*

Keywords: Tibial fractures; Fracture fixation, internal; Bone plates; MIPO; Treatment outcome.

Received: 05.02.2026, **Accepted:** 11.02.2026.

Ad-din Sakina Women's Medical College Journal. 2026; 7 (2) : 19-27

Introduction

The distal tibia is a part of the body that's very hard for doctors to fix when it gets broken. This is because of where it's located and the fact that it does not have a lot of soft tissue around it. The distal tibia is also very close to the ankle joint, which is important for being able to walk and move around. When the distal tibia gets broken it can be very hard to heal because it does not have a lot of blood flowing to it.[1] Extra-articular fractures of the tibia are a common type of broken bone in the lower leg. These types of breaks often happen because of accidents, such as car crashes or falls from high places.[2]

In the past doctors would often treat tibial fractures by keeping the leg still for a long time. However this can cause a lot of problems, such as the joint getting stiff the bone not healing properly and the leg getting shorter. It can also take a time for the person to be able to move around and do their daily activities again.[3] Because of these problems many doctors prefer to do surgery to fix the break. This is especially true for breaks that're not stable. Surgery can help the person get back to moving sooner and can also help the bone heal properly.

However surgery for tibial fractures can also be very challenging. One type of surgery called

1. Dr. Tapos Biswas, Assistant Professor, Department of Orthopedic Surgery, Dhaka Medical College Hospital, Dhaka, Bangladesh
2. Dr. Manashe Chanda, Lecturer, Department of Biochemistry, Tangail Medical College, Tangail, Bangladesh
3. Dr. Dewan Rakibul Islam, Assistant Professor, Department of Orthopaedic Surgery, International Medical College Hospital, Gazipur, Bangladesh
4. Dr. Kazi Karim Newaz, Junior Consultant, Department of Orthopaedics, Gopalganj Medical College Hospital, Gopalganj, Bangladesh
5. Dr. Md. Rakibul Islam, Junior Consultant, Department of Orthopaedic Surgery, Shahid Sayed Nazrul Islam Medical College Hospital, Kishoreganj, Bangladesh
6. Dr. A.R.M Masum Bhuiyan, Resident MS Orthopaedics, Department of Orthopaedic Surgery, Dhaka Medical College Hospital, Dhaka, Bangladesh
7. Dr. Muhammad Neamul Haque, Medical Officer, Department of Orthopaedic and Traumatology, Upazila Health Complex, Nasirnagor, Brahmanbaria, Bangladesh

***Correspondence:** E-mail: taposbiswas86@gmail.com

reduction and internal fixation requires the doctor to make a big cut in the leg and move the soft tissue around. This can cause a lot of problems, such as infection the bone not healing properly and the wound not closing.[4] Another type of surgery called fixation uses pins and frames to hold the bone in place. However this type of surgery can also cause problems, such as infection and the bone not healing properly.[5] There is another type of surgery called interlocking nailing that uses a rod to hold the bone in place. However this type of surgery can be very hard to do for breaks that are close to the ankle joint.[6]

A newer type of surgery called minimally invasive plate osteosynthesis (MIOP) is a more gentle way of fixing the break. This type of surgery uses a plate to hold the bone in place without having to make a big cut in the leg. This can help the bone heal faster. Can also reduce the risk of problems. By avoiding direct exposure of the fracture site, MIPO facilitates indirect fracture reduction and preserves the fracture hematoma, which is essential for bone healing.[7] The plate used in this type of surgery is specially designed to fit the shape of the tibia. This helps the doctor to put the plate in the place without having to make a big cut in the leg. This type of surgery has been shown to be very effective in helping the bone heal and in reducing the risk of problems.[8]

Anatomical distal tibial plates are side-specific and precontoured to match the medial surface of the tibia, enabling accurate alignment and stable fixation without extensive soft tissue dissection. This technique has been associated with favourable radiological union rates, early weight bearing, reduced postoperative complications, and improved functional outcomes.[9] Despite increasing adoption of MIPO with anatomical plates, evidence from prospective studies in low and middle-income countries, including Bangladesh, remains limited. This study aimed to evaluate the functional and radiological outcomes of extra-articular distal tibial fractures treated with anatomical plate fixation using the minimally invasive plate osteosynthesis technique.

Materials and Methods

Study Design, Setting, and Population: This prospective observational study was carried out in the Department of Orthopaedic Surgery at Dhaka Medical College Hospital, Dhaka, Bangladesh, between July 2020 and October 2022. Patients presenting with radiologically confirmed extra-articular distal tibial fractures were enrolled in the study. All participants underwent assessment and treatment following a uniform management protocol that was consistently applied throughout the study period.

Sample Size and Sampling Technique: The sample size was determined using previously reported rates of satisfactory functional outcomes, with the calculation based on a statistical power of 80% and a significance level of 10%. This yielded a required sample size of 26 patients. Nevertheless, disruptions associated with the COVID-19 pandemic affected patient follow-up, and complete data were ultimately obtained for 20 patients, who were included in the final analysis. Participant selection was carried out through purposive sampling, and eligibility was assessed according to predefined inclusion and exclusion criteria.

Eligibility Criteria: Patients were considered eligible for inclusion if they were older than 18 years, irrespective of gender, and had closed extra-articular distal tibial fractures classified as AO type 43-A1, 43-A2, or 43-A3. Only fractures presenting within three weeks of injury were included. Patients with open fractures, intra-articular involvement of the distal tibia, pathological fractures, neglected old fractures, or unstable medical conditions that substantially increased operative risk were excluded from the study.

Data Collection: Information was gathered using a pretested structured questionnaire designed to capture demographic characteristics, clinical and radiological findings, operative details,

postoperative outcomes, and any complications encountered during follow-up. Patients were reviewed at scheduled intervals and monitored until radiological union was achieved or the designated follow-up period was completed.

Study Variables: The study evaluated several demographic, clinical, and outcome variables. Demographic characteristics included age, sex, and occupation. Clinical parameters comprised the side of injury, mechanism of trauma, fracture pattern, and the interval between injury and surgical intervention. Outcome measures included the time required for radiological union, pain status at the final follow-up visit, ankle dorsiflexion, varus or valgus deformity, limb length discrepancy, postoperative complications, and functional recovery as measured by the Olerud–Molander Ankle Score.

Operational Definitions: Radiological union was considered present when bridging callus formation was visible across the fracture site with complete or near-complete disappearance of the fracture line, accompanied by painless weight bearing. Delayed union was defined as slower-than-expected fracture healing with evidence of ongoing healing potential. Non-union referred to failure of fracture healing by nine months after surgery, with no radiological signs of progression during the preceding three months. Full weight bearing was defined as the ability to support the entire body weight without pain, whereas partial weight bearing indicated the ability to bear approximately 50% of body weight.

Preoperative Assessment: All patients were initially assessed and stabilized in accordance with Advanced Trauma Life Support (ATLS) guidelines. A comprehensive clinical evaluation was performed, followed by radiographic examination using anteroposterior and lateral views of the affected limb, including both the knee and ankle joints. Standard preoperative investigations were completed to determine fitness for anesthesia and surgery. Prior to definitive fixation, the injured limb was immobilized with a posterior splint, elevated to reduce swelling, and managed with appropriate analgesia.

Surgical Technique: Surgery was carried out under spinal anesthesia with the patient positioned supine on a radiolucent operating table. A tourniquet was applied in all cases. Fracture fixation was performed using the minimally invasive plate osteosynthesis (MIPO) technique with an anatomically contoured distal tibial locking compression plate placed along the anteromedial aspect of the tibia. Indirect reduction methods under fluoroscopic guidance were used to restore alignment while preserving the surrounding soft tissues. Through a small incision over the medial malleolar region, the plate was introduced subcutaneously and advanced across the fracture site. Temporary stabilization was obtained with Kirschner wires, after which definitive fixation was achieved using a combination of locking and non-locking screws with adequate bicortical purchase. Following satisfactory fixation, the wound was closed in layers and a below-knee posterior plaster slab was applied.

Postoperative Management and Follow-up: Following surgery, limb elevation was maintained and early mobilization of the knee joint was encouraged. Patients were advised to ambulate with crutch support while avoiding weight bearing as tolerated. Ankle range-of-motion exercises were initiated after suture removal at two weeks. Partial weight bearing was permitted once radiological evidence of callus formation became apparent, and progression to full weight bearing was allowed after both clinical and radiological union had been confirmed. Regular follow-up evaluations were conducted for a minimum duration of six months to monitor fracture healing, functional recovery, and any postoperative complications.

Data Analysis: Data were compiled and analyzed using the Statistical Package for Social Sciences (SPSS), version 26.0. Descriptive statistics were

used to summarize patient characteristics, clinical variables, and outcomes.

Ethical Considerations: The study protocol was approved by the Ethical Review Committee of Dhaka Medical College (ERC-DME/ECC/2021/14). Written informed consent was obtained from all participants after explaining the study objectives, procedures, and potential risks in the local language.

Results

A total of 20 patients with extra-articular distal tibial fractures were included in the study. Male patients constituted the majority of the study population (60.0%), with a male-to-female ratio of 1.5:1. The mean (±SD) age of the patients was 43.55 (±11.49) years (range: 26–68 years), and the largest (30%) proportion of patients belonged to the 31–40 years age group (Table 1).

Table 1. Demographic Characteristics of the Study Participants (n = 20)

Variable	Category	*n*	%
Gender	Male	12	60.0
	Female	8	40.0
	Male : Female ratio	—	1.5 : 1
Age group (years)	18–30	3	15.0
	31–40	6	30.0
	41–50	5	25.0
	51–60	4	20.0
	61–70	2	10.0
Age (years)	Mean ± SD	43.55 ± 11.49	—
	Range	26–68	—

n; Number of cases, %; Percentage

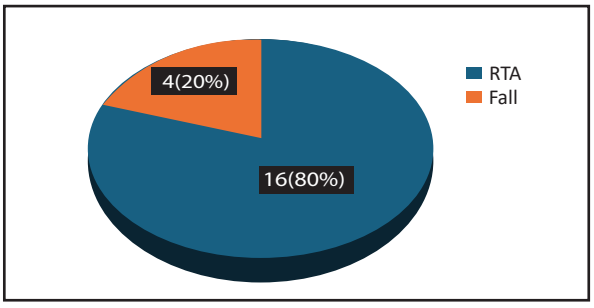

Figure 1: Pie diagram showing the mechanism of injury of study patients (n=20)

Figure 1 shows the mechanism of injury. Road traffic accident (RTA) was most common cause of injury up to the extent of 16(80.0%).

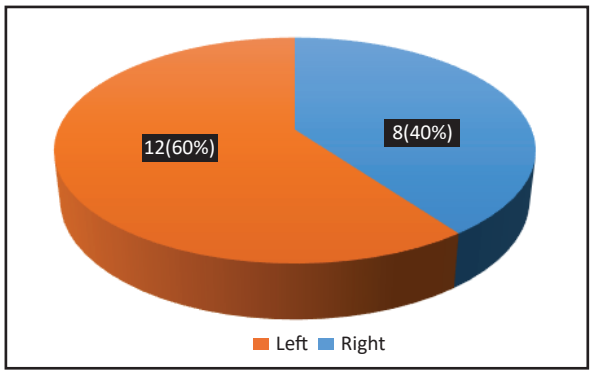

Figure 2: Pie diagram showing the side distribution of injured limb (n=20)

Figure 2 shows that among 20 patients, 12(60%) patients had injury on right side while 8(40%) patients had left sided injury.

Regarding fracture configuration, the majority of patients sustained AO type 43-A3 fractures (70.0%), followed by type 43-A2 fractures in 25.0% of cases, while only one patient (5.0%) had a type 43-A1 fracture. Assessment of soft tissue injury revealed that most patients had minimal soft tissue involvement, with 75.0% classified as Tscherne grade 0 and the remaining 25.0% as grade 1. No patients presented with grade 2 or grade 3 soft tissue injuries (Table 2).

Table 2: Fracture Type and Soft Tissue Injury Distribution (n = 20)

Variable	Category	*n*	%
AO fracture type	AO 43-A1	1	5.0
	AO 43-A2	5	25.0
	AO 43-A3	14	70.0
Tscherne soft tissue grade	Grade 0	15	75.0
	Grade 1	5	25.0
	Grade 2	0	0.0
	Grade 3	0	0.0

n; Number of cases, %; Percentage

Table 3 shows that the operative time for most of the patient's 16(80.0%) took ≤ 90 minutes and 4 (20.0%) patients took 91-120 minutes. Mean operative time was 84.5±11.1 minutes.

Table 3: Duration of surgery of the study patients (n =20)

Operative time	*n*	%
≤ 90 minutes	16	80.0
91-120 minutes	4	20.0
>120 minutes	0	0.0
Total	20	100.00
n; Number of cases, %; Percentage		

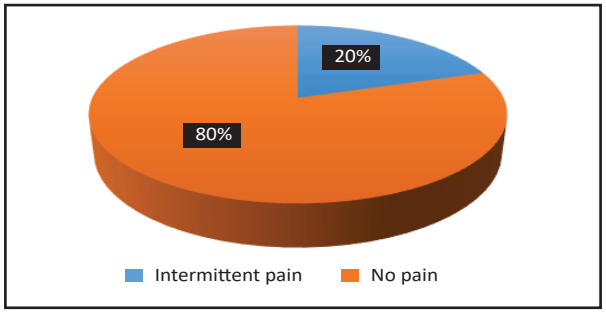

Figure 3: Pie diagram showing pain status of study patients (n=20)

Figure 3 shows the pain status of the study patients, 16 (80.0%) patients' complaints of no pain and 4 (20.0%) patients' complaints of intermittent pain.

Most patients achieved both full weight bearing and radiological union between 17 and 18 weeks (45.0%), as shown in Table 4. The mean time to full weight bearing and radiological union was 18.50 ± 1.93 weeks. No cases of delayed union or non-union were observed during the follow-up period.

Table 4: Time to Full Weight Bearing and Radiological Union (n = 20)

Outcome measure	Time interval	*n*	%
Full weight bearing	14–16 wks	4	20.0
	17–18 wks	9	45.0
	>18 wks	7	35.0
Radiological union	14–16 wks	4	20.0
	17–18 wks	9	45.0
	>18 wks	7	35.0
	Delayed union	0	0.0
	Non-union	0	0.0
wks; Weeks, *n*; Number of cases, %; Percentage			

Table 5 showing the range of motion, maximum 4 (20.0%) patients had ankle dorsiflexion at 0 to 5 degree and 11 (55.0%) patients had 6-10degreeofankle dorsiflexion then 5 (25.0%) patients had more than 10-degree ankle dorsiflexion. Mean ankle dorsiflexion was 10 ±3.97 degrees.

Table 5: Ankle dorsiflexion of the study patients (n=20)

Ankle dorsiflexion	*n*	%
≤ 5degree	4	20.0
6-10 degree	11	55.0
>10 degree	5	25.0
Total	20	100.00
n; Number of cases, %; Percentage		

Table 6 shows the walking capacity of the patients, in 16(80.0%) patient's walking capacity was same as before. But, 2(10.0%) patients had mild restriction to walk and 2(10.0%) patients used walking aids.

Table 6: Walking capacity of the study patients (n =20)

Walking capacity	*n*	%
Same as before	16	80.0
Mild restriction	2	10.0
Use walking aids	2	10.0
Total	20	100.0
n; Number of cases, %; Percentage		

Majority of the patients 16(80%) had no complications. Superficial infection was found in 02 (10.0%) patients, 01 (5.0%) patient had deep infection and 01 (5.0%) patient had ankle stiffness.

Table 7: Complications after surgery of the study patients (n =20)

Complications	*n*	%
Superficial infection	2	10.0
Ankle stiffness	1	5.0
Deep infection	1	5.0
Non-union	-	-
Implant failure	-	-
No complications	16	80.0
Total	20	100.0
n; Number of cases, %; Percentage		

Functional outcome assessment using the Olerud–Molander Ankle Score demonstrated favourable results in the majority of patients (Table 8). Excellent outcomes were observed in 25.0% of patients, while 55.0% achieved good functional recovery. Overall, 80.0% of patients attained a satisfactory outcome, whereas 20.0% had an unsatisfactory outcome. No patients were classified as having a poor functional outcome.

Table8: Functional Outcomes by Olerud–Molander Score (*n* = 20)

Outcome category	OMS score range	*n*	%
Excellent	91–100	5	25.0
Good	61–90	11	55.0
Fair	31–60	4	20.0
Poor	<30	0	0.0
Satisfactory (Excellent + Good)	—	16	80.0
Unsatisfactory (Fair + Poor)	—	4	20.0
n; Number of cases, %; Percentage			

A. Medial malleolar incision



B. Subcutaneous plate insertion



C. C-Arm View for confirmation

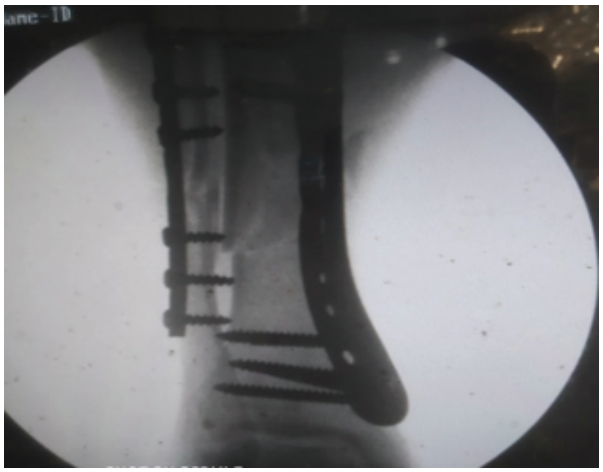

D. Completion of Screw fixation



E. Closure of wound



Figure 4: Intraoperative steps of minimally invasive plate osteosynthesis for distal tibial fracture.

All patients underwent fracture fixation using the minimally invasive plate osteosynthesis technique with an anatomically contoured distal tibial locking plate. The procedure was successfully completed through a limited medial incision with subcutaneous plate insertion under fluoroscopic guidance. Intraoperative images demonstrate key steps of the surgical technique, including medial malleolar incision, subcutaneous plate tunnelling, fluoroscopic confirmation of fracture reduction, completion of screw fixation, and wound closure (Figure 4).

Discussion

Extra-articular distal tibial fractures remain a therapeutic challenge because of the subcutaneous location of the bone, limited soft tissue envelope, and compromised blood supply.[10] In the present study, functional and radiological outcomes of extra-articular distal tibial fractures treated with anatomical plate fixation using the minimally invasive plate osteosynthesis (MIPO) technique were evaluated, demonstrating overall favourable clinical results.

The present study demonstrated that minimally invasive plate osteosynthesis (MIPO) using an anatomically contoured distal tibial locking plate provided favourable clinical, radiological, and functional outcomes in patients with extra-articular distal tibial fractures. The study population was predominantly male (60.0%) with a mean age of 43.55 ± 11.49 years, reflecting the greater exposure of economically active adults to high-energy trauma. Road traffic accidents accounted for 80.0% of injuries, consistent with previous studies by Ronga et al., Redfern et al., and Hasenboehler et al., which also identified road traffic accidents as the leading cause of distal tibial fractures among adults. These findings highlight the substantial burden of high-energy trauma in this patient population.[11]

Most fractures were classified as AO type 43-A3 (70.0%), while 75.0% of patients had Tscherne grade 0 soft tissue injury. The predominance of fractures with minimal soft tissue damage likely contributed to the favourable postoperative outcomes observed in this study. Similar fracture patterns and patient selection have been reported in previous studies, which demonstrated that preservation of the soft tissue envelope is a key determinant of successful fracture healing following MIPO.[12,13]

The mean operative time was 84.5 ± 11.1 minutes, and 80.0% of procedures were completed within 90 minutes, indicating that MIPO can be performed efficiently with adequate surgical expertise. Furthermore, all fractures achieved radiological union, with a mean union time of 18.50 ± 1.93 weeks, and no cases of delayed union or non-union were observed. These findings are comparable to previous studies reporting high union rates and satisfactory healing times following MIPO.[12,14] The excellent union rate in the present study is likely related to preservation of the periosteal blood supply and fracture hematoma, which are recognized biological advantages of minimally invasive fixation.[15]

Functional recovery was also encouraging. At final follow-up, 80.0% of patients were pain-free, 80.0%

regained their pre-injury walking capacity, and 80.0% achieved satisfactory functional outcomes based on the Olerud–Molander Ankle Score. Only four patients experienced fair outcomes, and none had poor functional recovery. These results are consistent with previous studies demonstrating good to excellent functional outcomes following MIPO for distal tibial fractures.[14,16] Early mobilization combined with stable fixation may have contributed to the satisfactory restoration of ankle function observed in the present study.

The postoperative complication rate was low, with 80.0% of patients experiencing no complications. Superficial infection occurred in only 10.0% of patients, while deep infection and ankle stiffness were each observed in 5.0% of cases. No implant failure or non-union was encountered. These findings agree with previous studies reporting that MIPO is associated with fewer wound complications than conventional open plating because it minimizes soft tissue dissection and preserves local vascularity.[17]

Conflict of Interest: The authors declare that there is no conflict of interest regarding the publication of this article.

Conclusion

Minimally invasive plate osteosynthesis using an anatomically contoured distal tibial locking plate provides stable fixation, promotes reliable fracture union, and results in favourable functional outcomes in extra-articular distal tibial fractures. The technique allows early weight bearing with a low complication rate while preserving soft tissue integrity and fracture biology. Based on the findings of this study, MIPO with anatomical plating appears to be a safe and effective treatment option for managing extra-articular distal tibial fractures.

References

1. Mauffrey C, McGuinness K. The management of distal tibial fractures: current concepts and controversies. Injury. 2012;43(12):2066-2073.

2. Hebert-Davies J, Kleweno CP, Nork SE. Contemporary Strategies in Pilon Fixation. J Orthop Trauma. 2020 Feb;34 Suppl 1:S14-S20.

3. Russell TA. Fractures of the tibial diaphysis. In: Levine AM, editor. Orthopaedic knowledge update: trauma. Rosemont (IL): American Academy of Orthopaedic Surgeons; 1996. p. 171-179.

4. Ali SI, Ravikumar K, Sheth S, et al. Evaluation of the functional outcome in distal tibia fractures managed by MIPPO technique using distal tibia locking plate. Int J Orthop Sci. 2017;3(2):441-444.

5. Neinaa H, Hannout Y, Wahab AM. Evaluation of treatment of distal tibial fractures using the minimally invasive percutaneous plate osteosynthesis technique. Menoufia Med J. 2016;29(3):691-696.

6. Reddy RM, Kumar AV, Shaik T. Outcome of distal tibia fractures managed with locking compression plate using MIPPO technique. Int J Orthop Sci. 2019;5(3):304-310.

7. Wagner M. General principles for the clinical use of the LCP. Injury. 2003 Nov;34 Suppl 2:B31-42.

8. Hak DJ, Toker S, Yi C, et al. The influence of fracture fixation biomechanics on fracture healing. Orthopedics. 2010 Oct;33(10):752-755.

9. Rudloff MI. Fractures of the lower extremity. In: Canale ST, Beaty JH, editors. Campbell's operative orthopaedics. 12th ed. Philadelphia (PA): Elsevier Mosby; 2013. p. 2690-2701.

10. Rahman MA, Sagir MG, Muniruzzaman M, et al. Management of distal tibial fracture (AO type 43-A) by MIPO with precontoured distal tibial

locking plate. J Patuakhali Med Coll. 2022;1(1):15-21.

11. Qasem FH, Ahmed KE, Islam MS, et al. Management of Fractures of the Distal Third of Tibia by Distal Tibial Locking Plate by MIPO Technique. Mymensingh Med J. 2021 Jan;30(1):148-153.

12. Hossain SME, Hawlader AR, Alam MS, et al. Unstable distal tibia fracture management by anatomically contoured plate with MIPO technique. Bangladesh Armed Forces Med J. 2023;56(1):1-6.

13. Gueorguiev B, Moriarty TF, Stoddart M, et al., editors. Apley & Solomon's system of orthopaedics and trauma. 10th ed. Boca Raton (FL): CRC Press; 2017. p. 711-754.

14. Estrada-Villaseñor E, Meneses A, Valdés-Flores M, et al. Giant cell tumor of bone: current treatments and potential therapeutic alternatives. Am J Cancer Res Rev. 2020;4:1-13.

15. Nyary T, Scammell BE. Principles of bone and joint injuries and their healing. Surgery (Oxford). 2018;36(1):7-14.

16. Islam MK, Islam MS, Das AK, et al. Evaluation of the results of treatment of distal tibial fracture by minimally invasive locking plate osteosynthesis. Planet (Barishal). 2020;4(2):52-56.

17. Akram W, Mahto AK, Alam M. Evaluation of results of minimally invasive plating osteosynthesis (MIPO) technique in the treatment of fractures of distal tibia. Int J Res Orthop. 2017;3(1):7-11.