Case Report

Iatrogenic Cushing's Syndrome and Severe Corticosteroid-Induced Osteoporosis Masking Advanced Chronic Tophaceous Gout: A 14-Year Cautionary Tale

*Rizwan ASM[1], Akhter S[2]

Abstract

Long-term, unmonitored glucocorticoid administration carries an immense risk of multi-systemic iatrogenic complications. We report the case of a 56-year-old female presenting with severe deforming arthritis, multiple vertebral compression fractures, secondary diabetes mellitus, and profound secondary adrenal insufficiency following 14 years of self-administered daily high-dose dexamethasone (15 mg/day). The steroid therapy was initially initiated for uncharacterized arthritis, masking an underlying, relentlessly progressing chronic tophaceous gout. Attempts to discontinue the steroid repeatedly triggered life-threatening adrenal crises characterized by severe rebound pain, vomiting, and vertigo. Laboratory and radiological investigations confirmed advanced tophaceous disease, profound osteopenia with multiple compression fractures resulting in a 2-inch loss of height, and a serum uric acid level of 13 mg/dL. This case underscores the catastrophic consequences of unregulated over-the-counter availability and unmonitored administration of potent corticosteroids, particularly in resource-limited clinical environments.

Keywords: Cushing syndrome; Iatrogenic; Gout; Osteoporosis; Glucocorticoids

Received: 17.06.2026, **Accepted:** 19.06.2026 .

Ad-din Sakina Women's Medical College Journal. 2026; 7 (2) : 37-40

Abstract

Gangrenous cholecystitis (GC) is a serious complication of acute cholecystitis.[1,2] GC is seen in 10%–40% of patients with acute cholecystitis.[3-5] GC has been described since 1894, and figures vary depending on the percentage of acute cholecystitis (AC) that GC makes up. GC patients tend to be sicker than the average AC patients, and their surgical procedure tends to be more challenging and is associated with an increased risk of morbidity and mortality when compared to all causes of AC.[6] GC risk factors include diabetes mellitus, males, older age, elevated white blood cells, and coronary heart disease.[2,3] GC is the progression of AC, which is commonly due to obstruction of the cystic duct due to an impacted stone, which commonly dislodges on its own and does not progress to GC. If the stone does not dislodge, then there will be vascular compromise and epithelial injury leading to ischemia locally and necrosis of that region's gallbladder wall.

1. Dr. A S M Rizwan, Associate Professor, Department of Medicine, Ad-din Sakina Women's Medical College, Jashore

2. Dr. Shahida Akhter, Associate Professor, Department of Physiology, Bangladesh Army Medical Corps.

***Correspondence:** E-mail: dr.asmrizwan@gmail.com

These patients will require early interventions to decrease morbidity and mortality.[7,8] The incidence of GC is more common in older patients and is associated with a higher white blood cell count (WBC) and diabetes.[9]

Case Presentation

A 56-year-old female patient had presented to outpatient department with severe, generalized, deforming joint pain, progressive physical disability, and an observed 2-inch reduction in her height over the preceding decade.

Fourteen years prior, she had visited a local physician for vague joint pains. She was told it was a suspected form of "arthritis" and was prescribed a short 7-day course of oral dexamethasone. Experiencing immediate and dramatic symptomatic relief, she independently opted to continue the medication. Over the next 14 years, she took an astonishing daily dose of 15 mg of oral dexamethasone. Midway through this period, she developed secondary diabetes mellitus as an iatrogenic consequence of the steroid abuse and was initiated on oral Metformin 500 mg twice daily.

On detailed systemic inquiry, the patient reported multiple previous attempts to taper or discontinue the dexamethasone. Each attempt invariably precipitated severe, debilitating withdrawal episodes characterized by unremitting, generalized rebound musculoskeletal pain, persistent vomiting, and profound vertigo, which were clinically diagnostic of an impending secondary adrenocortical crisis due to deep HPA axis suppression. Fearing these symptoms, she returned to her daily 15 mg dexamethasone regimen each time.

Physical examination revealed classic features of long-standing iatrogenic Cushing's syndrome alongside advanced, asymmetrical joint inflammation. Marked, hard subcutaneous nodules and asymmetric deformities were visible over her bilateral wrists, proximal interphalangeal (PIP) joints, distal interphalangeal (DIP) joints, and first metatarsophalangeal (MTP) joints.



Figure 1: *Clinical photograph of the patient's hands showcasing severe, asymmetric deforming arthritis with multiple visible subcutaneous gouty tophi over the small joints of the fingers and wrists.*



Figure 1: *Clinical photograph of the patient's right foot displaying a large gouty tophus involving the first metatarsophalangeal joint with overlying cushingoid skin changes.*

Laboratory evaluation revealed a markedly elevated serum uric acid level of 13 mg/dL (normal range: 2.4–6.0 mg/dL), indicative of severe, uncontrolled hyperuricemia. Marked systemic inflammation was present, with an erythrocyte sedimentation rate (ESR) of 82 mm in the first hour and a c-reactive protein (CRP) level of 54 mg/L. Her random blood sugar (RBS) was elevated at 9.7 mmol/L, reflecting suboptimal glycemic control under high-dose steroid pressure. Her serum creatinine was stable at 0.9 mg/dL.

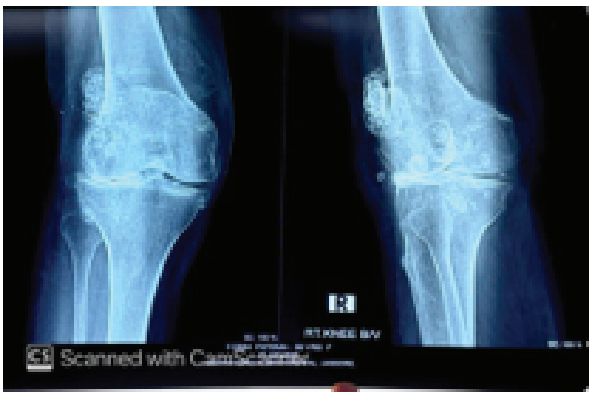

Figure 3: *Plain radiograph of the right knee showing extensive, calcified soft-tissue tophaceous deposits in the periarticular/patellar region along with profound joint space narrowing.*

Radiological investigations of her knees and lumbar spine confirmed widespread tissue and bony damage.

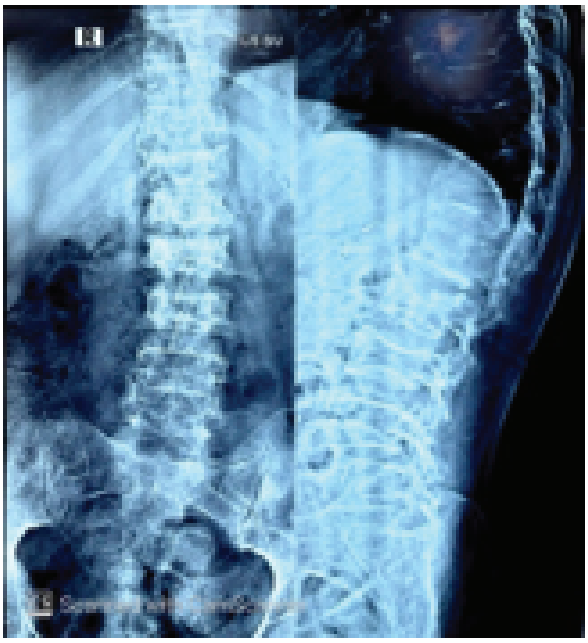

Figure 4: *Plain anteroposterior and lateral radiograph of the lumbosacral spine demonstrating severe, diffuse osteopenia and multiple biconcave, "codfish" vertebral compression fractures, correlating with her 2-inch height loss.*

Due to acute financial constraints, a formal dual-energy x-ray absorptiometry (DEXA) scan to quantify bone mineral density and a short synacthen (ACTH stimulation) test to map her exact adrenal reserve could not be executed. However, her clinical presentation of severe, recurrent withdrawal-induced hemodynamic instability and vomiting provided clear evidence of profound adrenocortical insufficiency.

The immediate management strategy required stabilizing her severe systemic pathologies while avoiding an acute adrenal crisis. She was maintained on her baseline morning dose of Dexamethasone 15 mg OD, with a structured plan for an extremely gradual, long-term endocrinological taper once her acute joint inflammation was under control. To aggressively target her severe hyperuricemia and prevent further tophaceous deposition, she was started on Febuxostat 80 mg OD. For her severe steroid-induced osteoporosis, she was prescribed Alendronic acid 70 mg combined weekly with vitamin D3 2800 IU, alongside Rabeprazole 20 mg OD for gastric cytoprotection. Unfortunately, the patient did not return for her scheduled follow-up appointments and was lost to further monitoring.

Discussion

This case illustrates the extreme, combined clinical toll of iatrogenic Cushing's syndrome, secondary adrenal insufficiency, and steroid-induced osteoporosis (SIO), which directly masked advanced chronic tophaceous gout. A daily intake of 15 mg of dexamethasone is a massive dose, approximately equivalent to 100 mg of prednisone per day. Glucocorticoids administered at this magnitude for over a decade completely suppress the paraventricular nucleus of the hypothalamus and the anterior pituitary gland, inducing profound atrophy of the adrenal cortex.[3] The patient's recurring presentation of severe vomiting, vertigo, and agonizing rebound pain upon withdrawal represents classic, dangerous clinical features of secondary adrenal insufficiency.[4]

Simultaneously, chronic glucocorticoid exposure stands as the primary iatrogenic driver of secondary osteoporosis. Glucocorticoids directly accelerate osteocyte and osteoblast apoptosis while upregulating RANK-ligand expression, triggering an initial phase of aggressive bone resorption followed by a permanent halt in bone formation.[5] This pathophysiology is vividly displayed in the patient's spine radiograph, showing classic "codfish" vertebral deformities and multiple compression fractures that cost the patient two inches of height.

The most unique aspect of this case is how these massive steroid doses interacted with her

underlying, unmanaged chronic tophaceous gout. Gout is a metabolic disease characterized by the systemic deposition of monosodium urate (MSU) crystals. While high-dose dexamethasone effectively shut down the acute, neutrophilic inflammatory cascades that cause painful gouty flares, it exerted zero impact on the severe hyperuricemia itself. As a result, her serum uric acid climbed to a critically high level of 13 mg/dL, facilitating relentless, silent crystal deposition directly into the joints and soft tissues. This produced the advanced, asymmetric joint destruction and prominent tophi seen on her hands and feet, as well as the prominent calcified tophaceous masses noted on her knee radiograph. Glucocorticoid induced diabetes mellitus (GIDM) is another concern that had menifested in our patient. Age of the patient, type of steroid used, duration and route all play integral part in developing the secondary diabetes. In a research that studied the incidence of GIDM among rheumatic and renal patient, 66.5% study subjects developed diabetes over a course of four weeks.[6] They have postulated that, for such patients with long term steroid use, age and estimated glomerular filtration rate are important predictors of GIDM.

In many low- and middle-income countries, including resource-limited regions of Bangladesh, potent steroids are frequently dispensed without a valid prescription or taken continuously by patients without laboratory monitoring.[7] When financial barriers prevent confirmatory gold-standard diagnostics—such as DEXA scans or ACTH stimulation testing—clinicians must rely entirely on precise physical examinations, baseline biochemistry, and classic radiographic features to direct life-saving care. It is mandatory to take responsibility of prescribing glucocorticoids in right causes, for right duration and in right dose. This is crucial to maintain steroid stewardship and make it a prescription-only medication to avoid catastrophic clinical outcome like this case.[8]

References

1. Da Silva JA, Jacobs JW, Kirwan JR, et al. Safety of low dose glucocorticoid treatment in rheumatoid arthritis: published evidence and prospective trial data. Ann Rheum Dis. 2006 Mar;65(3):285-293.

2. Adler RA, Curtis JR, Saag KG, et al. Glucocorticoid-induced osteoporosis. In: Marcus R, Feldman D, Nelson DA, Rosen CJ, editors. Osteoporosis. 3rd ed. San Diego (CA): Elsevier Academic Press; 2008:1135-1166.

3. Krasner AS. Glucocorticoid-induced adrenal insufficiency. JAMA. 1999 Aug 18;282(7):671-676.
4. Hochberg Z, Pacak K, Chrousos GP. Endocrine withdrawal syndromes. Endocr Rev. 2003 Aug;24(4):523-538.

5. Kanis JA, Johansson H, Oden A, et al. A meta-analysis of prior corticosteroid use and fracture risk. J Bone Miner Res. 2004 Jun;19(6): 893-899.

6. Katsuyama T, Sada KE, Namba S, et al. Risk factors for the development of glucocorticoid-induced diabetes mellitus. Diabetes Res Clin Pract. 2015 May;108(2):273-279.

7. Mittal R, Kalra S. Steroids - good, bad, and ugly. Bangladesh J Endocrinol Metab. 2023 Sep-Dec; 2(3):121-122.

8. Kalra S, Kumar A, Sahay R. Steroid Stewardship. Indian J Endocrinol Metab. 2022 Jan-Feb;26(1) :13-16.